

2.6 ORAL LICHEN PLANUS

Introduction

Lichen planus is primarily a dermatologic disorder in which various mucosal surfaces may be involved either independently, concurrently with cutaneous involvement, or serially. Oral mucosa, however, is more frequently affected than other mucosal sites. The prevalence of oral lichen planus in random population samples in India varies from 0.1% to 1.5%. Although various factors are suggested to be involved in the pathogenesis of this disease, its exact etiology is still not clear. Interestingly, 93% of individuals with oral lichen planus are tobacco users and a majority of them chew as well as smoke tobacco. Tobacco use also influences the natural history of oral lichen planus. Although tobacco is not considered as an etiologic agent for this condition, these observations are relevant in the management of oral lichen planus cases.

The precancerous nature of oral lichen planus is still uncertain. Currently, this condition is categorized as a "probable precancerous condition". Longitudinal studies on oral lichen planus patients from India demonstrated a high but statistically insignificant excess risk for oral cancer in this condition. Therefore, a careful long-term observation of oral lichen planus patients is highly desirable.

Diagnostic criteria

Oral lichen planus is diagnosed on the basis of the presence of Wickham's striae that can be faint or prominent. Several pearly white papules which are the basic eruptive elements in this condition can also be discerned in the striae or, occasionally, oral lichen planus may entirely consist of these papules. Oral lichen planus (Fig. 1), like its cutaneous counterpart, occurs in various morphologic forms. In this section the most frequent forms are described.

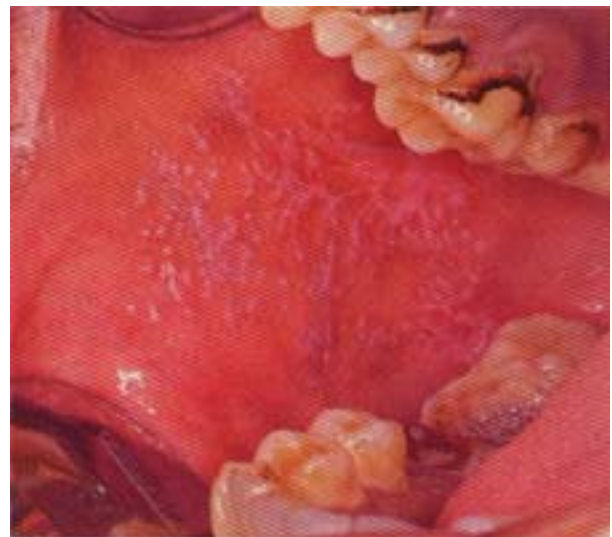

Fig. 1. Lichen planus in the right buccal mucosa of a betel-quinid chewer. Note the reticular arrangement of white striae and numerous pearly white papules.

Clinical aspects

The buccal mucosa is the most frequently (84%) affected site. Generally, oral lichen planus is asymptomatic. Patients with erosive lichen planus, however, may experience burning sensation or even pain at the affected area.

Reticular form : The most common clinical type is the reticular form which is marked by crisscrossing, lacey white striae (Fig. 2) , giving it a white lace-like appearance.

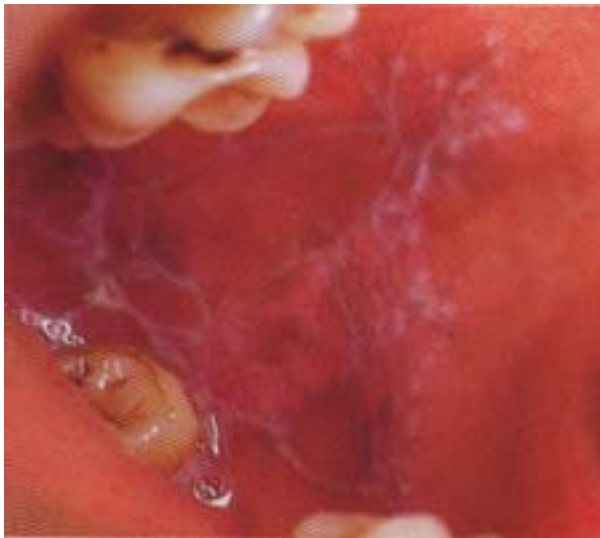

Fig. 2. A reticular form of lichen planus in the left buccal mucosa of a woman

Plaque form : The plaque form of lichen planus consists of either a pearly white or grayish white plaque (Fig. 3). At times , it is difficult to distinguish a plaque form of oral lichen planus from a leukoplakia solely on clinical basis. The presence of Wickham's striae, papules or other morphological forms may often help in distinguishing it from leukoplakia,

Erosive form : Erosive form of lichen planus consists of erosions of various sizes on the oral mucosa (fig. 4). Often, Wickham's striae or papules can be discerned on the erosion.

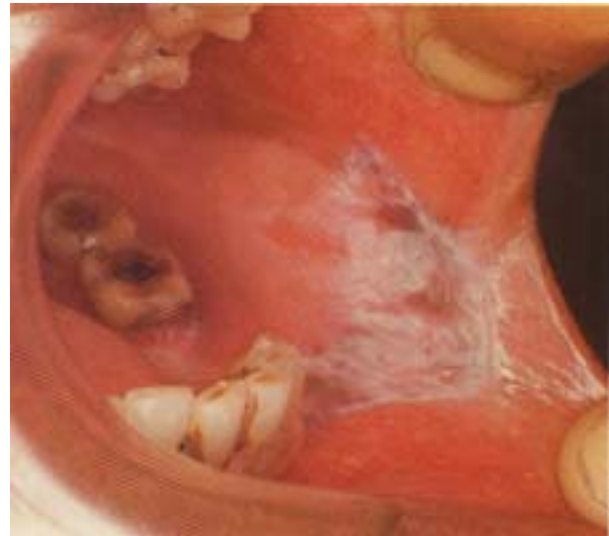

Fig. 3. A plaque form of lichen planus in the left commissure and the buccal mucosa. Note the erosive and pigmented areas on the lesion.

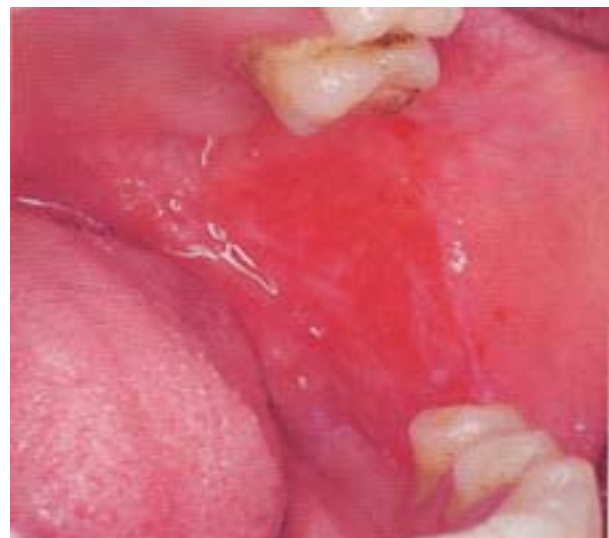

Fig.4. An erosive form of oral lichen planus in the left buccal mucosa of a female.

70 Tobacco-related Oral Mucosal Lesions and Conditions

About 20% of oral lichen planus cases exhibit erosive or atrophic areas. Erosive lichen planus may cause burning sensation or pain of the oral mucosa and it often runs a

prolonged course. Erosive lichen planus shows a higher risk for cancer development, when compared to other variants of oral lichen planus.

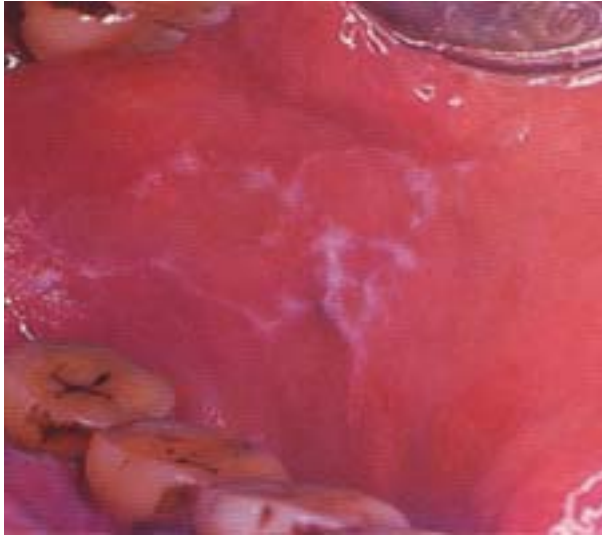

Fig.5. An annular form of lichen planus in the left buccal mucosa.

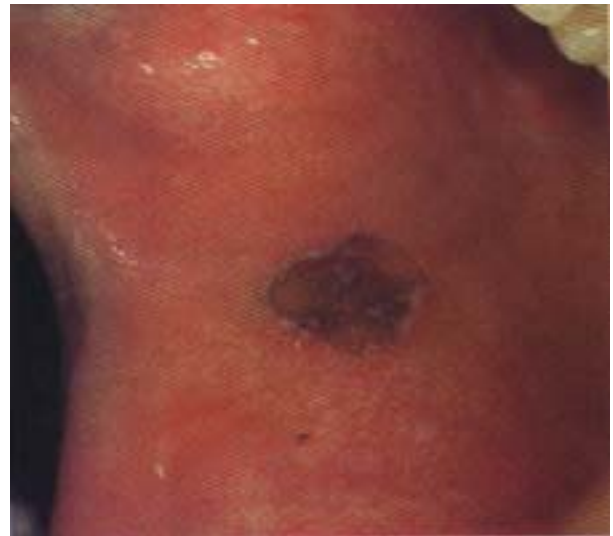

Fig. 7. Annular form of oral lichen planus associated with pigmentation on the right buccal mucosa. There was no pigmentation anywhere else in the oral mucosa.

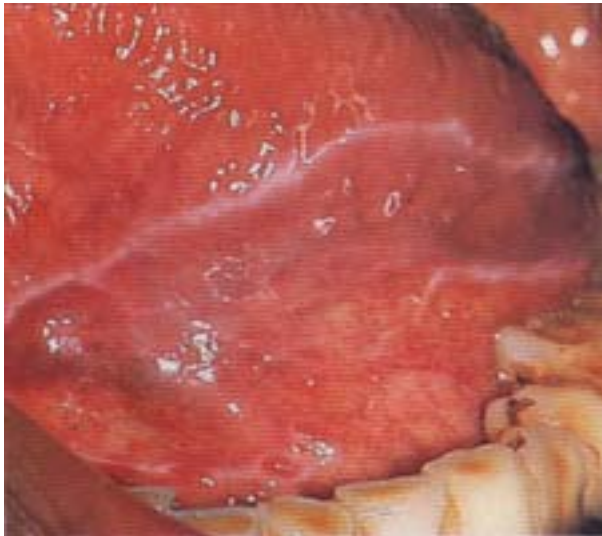

Fig.6. A linear form of lichen planus in the left margin of the tongue and at its mucosal reflection on the floor of the mouth.

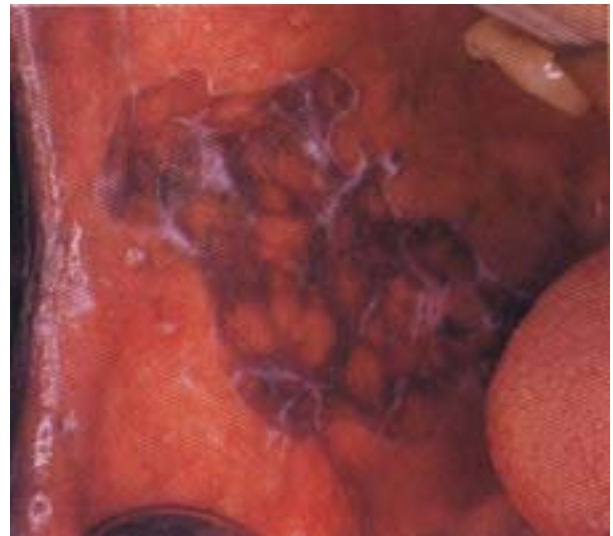


Fig. 8. Reticular and papular forms of lichen planus associated with pigmentation in the right buccal mucosa.

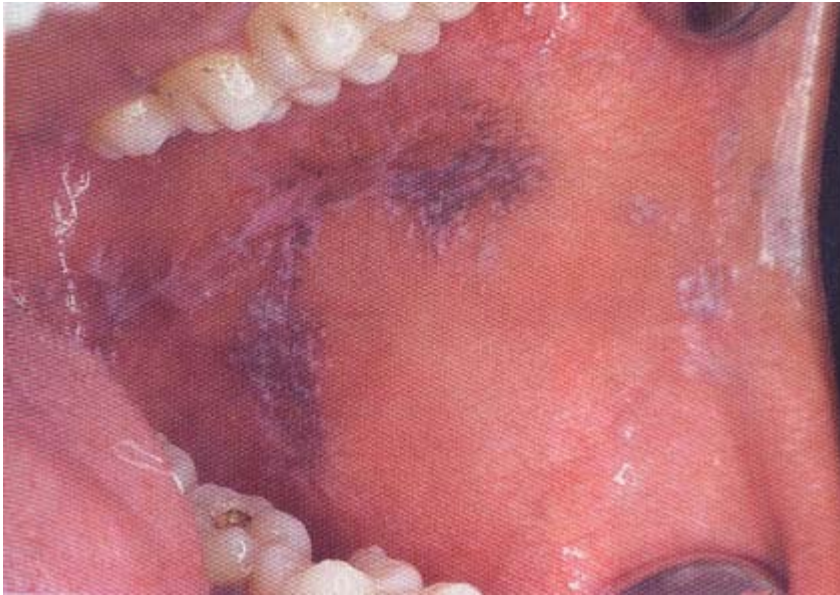

Fig. 9. Reticular and papular forms of lichen planus associated with pigmentation in the left buccal mucosa.

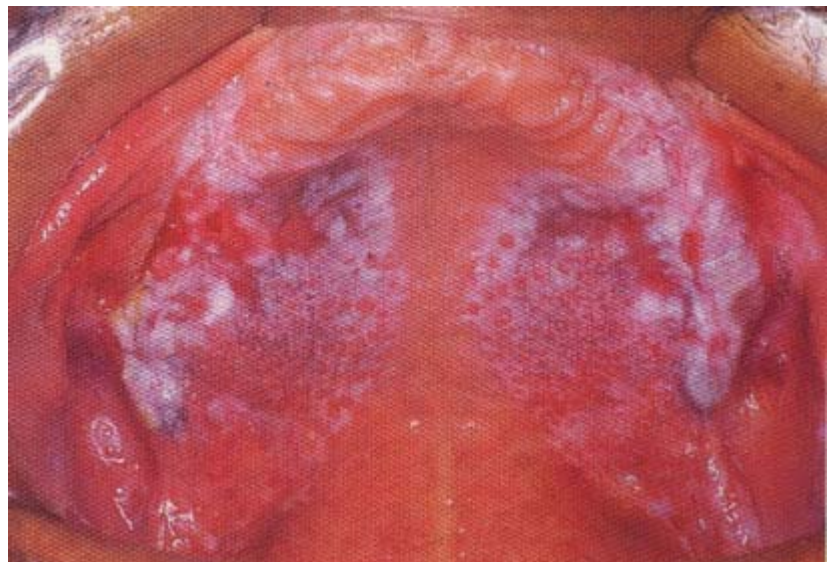
Annular and linear forms: Annular and linear forms consist of striae that occur in a circular (Fig.5) and linear (Fig. 6) fashion.

Oral lichen planus associated with pigmentation: In about 11% of cases, oral lichen planus may be associated with pigmentation(Figs. 7,8 &9) . It may begin

either with pigmentation, or the pigmentation may appear subsequently. While the appearance of pigmentation in cutaneous lichen planus indicates the resolution of the condition, no such conclusions can be made in regard to its oral counterpart.

Multiple forms : Occasionally, several forms of oral lichen planus may coexist (Fig.10),

Fig. 10. An erosive, plaque, reticular and papular (very small papules forms of lichen planus on the palate.



and one form may change into another over time.

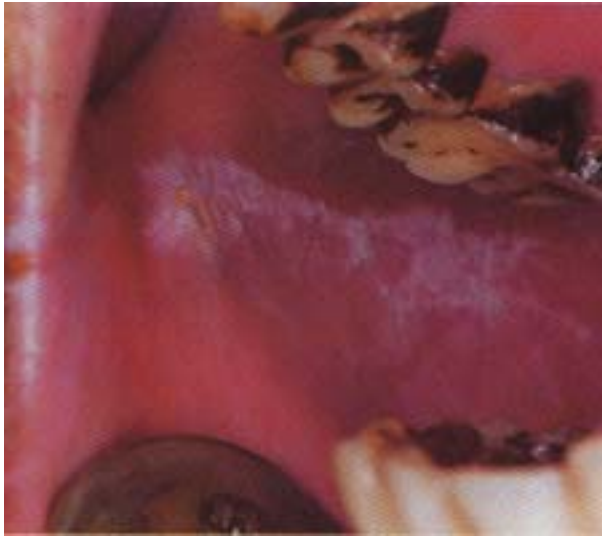

Fig. 11. A pearly white plaque of lichen planus in the right buccal mucosa of a man. He also had lichen planus on the left buccal mucosa.

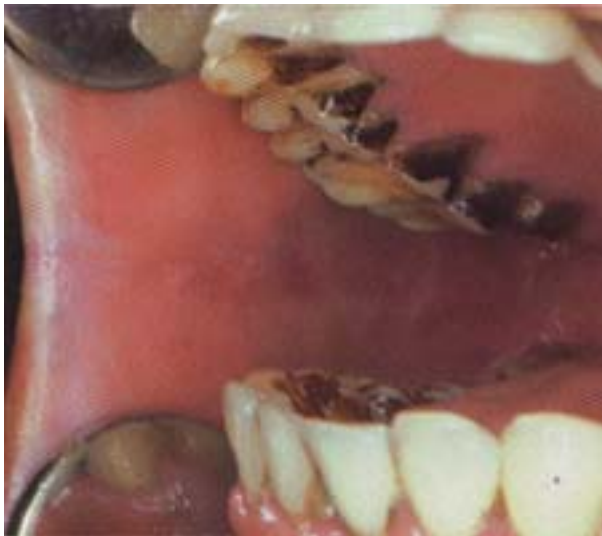

Fig.12. Five years later, the plaque shown in Fig.11 regressed almost completely. Subsequent observations for five years did not show recurrence.

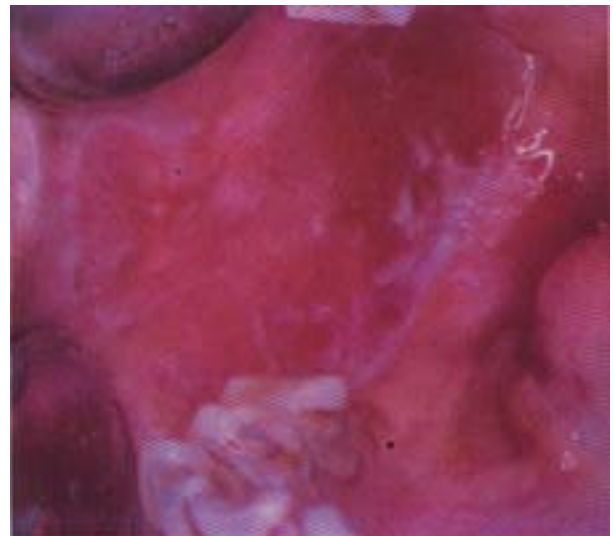


Fig. 13. An erosive form of lichen planus in the right buccal mucosa of a female betel- quid chewer. Note the few papules on the erosion and white striae on its periphery. A biopsy from the erosion showed microscopic features consistent with oral lichen planus as well as epithelial dysplasia. This picture was taken in 1971.

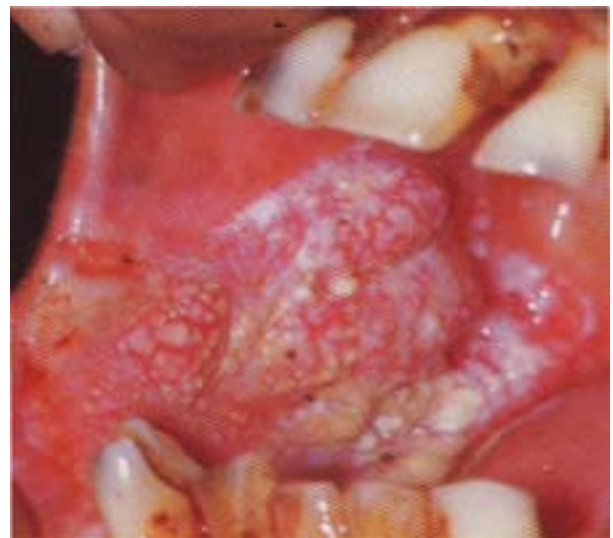


Fig.14. In 1992, cancer developed in oral lichen planus shown in Fig.13.

Natural history

Oral lichen planus may remain stationary (in 87% to 93% cases), regress spontaneously (in 7% to 13% cases) (Figs. 11 & 12), and recur in about 3% of the cases. Malignant transformation was also observed in few cases of oral lichen planus (Figs. 13 & 14).

Malignant transformation: In a sample of 722 cases of oral lichen planus that were followed-up for 10 years (mean, 5.1 yr) in Ernakulam District, about 0.4% showed malignant transformation (Figs. 13 & 14). This was not statistically significant to confirm its precancerous nature. As compared

to other forms of lichen planus, the erosive form is more prone to the development of cancer. In nonerosive forms, cancer development was observed to be preceded by the appearance of erosive areas.

Conclusions

Although the precancerous nature of oral lichen planus is still not settled, patients with this condition must be carefully evaluated and observed. The fact that a vast majority of oral lichen planus patients in India use tobacco, which is a known etiologic factor for oral cancer, highlights the need to educate all patients with this condition to discontinue their tobacco use.